

Cystic Hygromas - Our Experience

Jyotirmoy Phookan¹, Pritam Chatterjee²

¹ (Associate Professor, Department of ORL & HNS, Gauhati Medical College & Hospital, Assam, India)

² (Senior Resident, Department of ORL & HNS, Bankura Sammilani Medical College & Hospital, West Bengal, India)

Abstract: Cystic hygromas are rare tumours. The pathophysiology lies in occlusion of lymph channels. It may present as a congenital swelling or in adulthood. There are various chromosomal anomalies associated with it. We here have are presented a series of 9 patients of cystic hygromas and their management. Though easy to diagnose clinically, it needs good radiological evaluation. Complete surgical excision is possible even in very extensive lesions.

Keywords: Lymphangioma, Cystic Hygroma, Spinal Accessory Nerve

I. Introduction

Hygroma in greek means water filled tumour. Cystic hygromas are type of lymphangiomas, first described by Olaus Redenbacker and Thomas Bertholin in 1828. Lymphangiomas can be microcystic, macrocystic and cystic hygromas. There are three theories proposed for its pathogenesis - firstly blockage or arrest of normal growth of primitive lymph channels, secondly primitive lymph sac fails to reach the venous system & thirdly lymphatic tissue lies in wrong place. Cystic hygromas, account for more than 90% of the lymphangiomas in the head and neck region. The other common areas are axilla, shoulder, chest wall, mediastinum, abdominal wall and thigh^[1]. Surgical excision is the best treatment. Sclerotherapy can be an alternative treatment. Bleomycin, tetracycline, doxycycline, dextrose, OK-432 have been used for the sclerotherapy. Most of these agents, except ok -432, cause extensive peri-lesional fibrosis which may complicate the salvage later^[2].

II. Materials And Method

This prospective study was conducted in Department of ORL & HNS, Gauhati Medical College & Hospital, a tertiary care centre in India. In the study period of 5 years, from July 2010 to June 2015, a total of nine patients were included in this study. A detailed history and through clinical examination was done in all the patients. Suspected cystic hygroma patients were evaluated preoperatively with ultrasound and fine needle aspiration cytology, & were included in the study based on cytopathology. Patients with extensive disease were also subjected to MRI for better delineation of the disease. All patients were operated by the author under general anesthesia for attempt of total excision of same, with consent. All surgical observations are recorded. No sclerotherapy was used in this series prior or post surgery. None of the patients received any form of treatment prior inclusion in this study. All patients are under clinical and radiological follow up till date.

III. Results

During this five year study period, nine patients underwent complete diagnostic algorithm, appropriately planned management and are still under follow-up till date. All the patients were below two years except one who was of 22 yrs of age. Two patients were female and rest were male. None of the patient's mother had any history of notable obstetric event. Questions were directed to rule out hydramnios of each child during the pregnancy of their mothers. None on the mothers reported of any suspicious anomaly scans.

The commonest complaint was difficulty in feeding, which was presenting complaint in eight patients. One patient's parents also complained of respiratory difficulty during sleep. The adult patient complained of swelling which caused with cosmetic disfigurement. No patient presented with signs of recurrent infection, haemorrhage or discharging sinus formation.

All the patients were investigated with ultrasonographic evaluation for diagnosis. Following diagnosis, they were considered for various available treatment options. All patients were planned for total excision. In this series of nine patients, all the patients were planned for surgery for the indication of difficulty in feeding, except the one adult patient who was operated for cosmetic indication. No sclerotherapy was used in this series prior or post surgery. None of the patients received any form of treatment prior inclusion in this study.

Figures

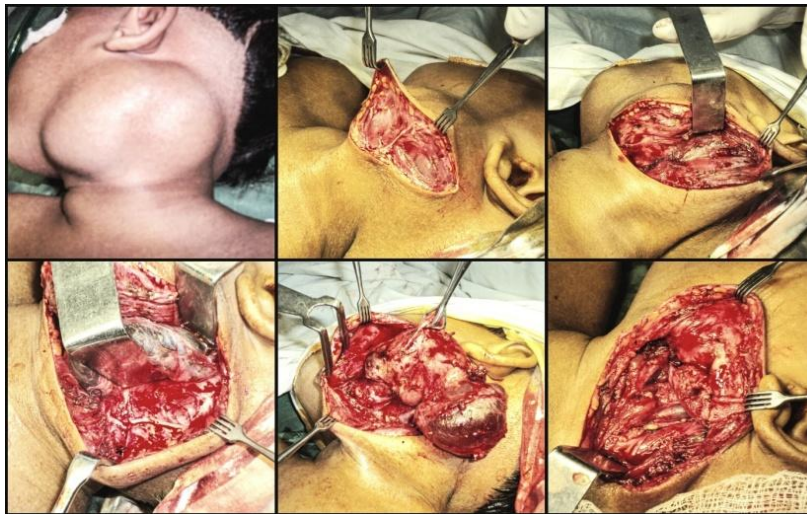


Figure 1. (A) Clinical Photograph Of Patient (B) Horizontal Cervical Incision (C) Flap Elevation & Dissection (D) Relation With Accessory Nerve (E) Dissection Of Cystic Hygroma (F) Post Excision Surgical Field

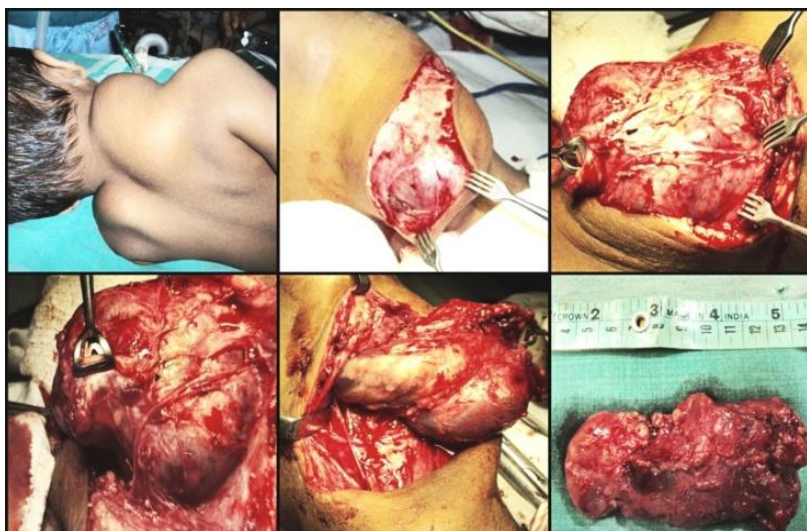

Figure 2. (A) Clinical Photograph Of Patient (B) Horizontal Cervical Incision (C) Flap Elevation & Dissection (D) Relation With Accessory Nerve (E) Dissection Of Cystic Hygroma (F) Post Excision Surgical Specimen

For surgical planning, every patient underwent MRI evaluation which depicted extent of lesion and its relationship with important nerves & vessels. All preoperative evaluations were within normal limits with no evidence of any syndromic associations. All the patients were operated under general anaesthesia with endotracheal intubation which went uneventful except in one patient where the anaesthetist had to use flexible bronchoscope because of the lesion pushing the floor oral cavity up thereby reducing the accessibility of the airway by laryngoscope.

All the patients were operated by a transverse cervical incision. Total excision could be done in all patients. In all the cases, we have observed there is involvement of the posterior triangle. Surgical exploration showed the intimacy of the spinal accessory nerve with the lesion which was always found to be wrapped around spinal accessory nerve. Negative suction drain was used in all the patients. Immediate post operative period was uneventful. Average hospital stay was 3 days.

In our series, one patient had marginal mandibular paresis which recovered within 3 months & another patient had difficulty in articulation of speech because of the surgical excision the cyst from the lateral border of the tongue that needed subsequent speech therapy. All patients are under clinical and radiological follow up with a maximum of 5 years to minimum of 1 year. There is no recurrence or any evidence of nerve palsies till date.

IV. Discussion

Lymphangiomas are rare congenital malformations of the lymphatic system that may occur anywhere in the body. They can be classified as microcystic (i.e. capillary haemangioma), macrocystic (i.e. cavernous haemangioma) and cystic hygroma^[3].

The incidence of cystic hygroma is 1.2 – 2.8 per 1000 birth^[3]. In about 80 % of instances, the location of cystic hygromas is cervico-facial region^[5]. Capillary haemangiomas are mostly found in suprahyoid areas like tongue and oral cavity where as cystic hygromas are most common in the neck. In the neck, anterior triangle of the neck is frequently involved. Cystic hygroma may be localised in the parotid area and is the most common congenital lesion of the parotid^[5]. Therefore, cystic hygroma should always be considered first in the preliminary differential diagnosis of cystic lesion with onset at birth in above mentioned locations.

More than 60% have onset at birth and upto 90 % becomes overt by age of two years. The nascent appearances of cystic hygroma in adults are scarcely reported in literature. Some case reports depict post-traumatic appearance of cystic hygroma in previously normal adults. These might represent the dormant variety of cystic hygroma that can appear at any age and trauma might be a coincidental event in those cases.^[6]

The commonest presenting symptom is swelling in the neck which may be very small at birth and may go unnoticed^[6]. There may be difficulty in feeding in the child because of infiltration of the tongue and the floor oral cavity. Invasiveness of the lesion may also give rise to respiratory obstruction. Macroglossia can be presenting symptom because of the infiltration by lymphangiomatous tissue to tongue which can also cause tongue fall back and respiratory difficulty. In rare instance squamous carcinoma may arise from these lesions^[9].

Cystic hygromas are benign lesions; however complications may arise. It can get infected from time to time, usual source of infection being seeding from secondary focus of infection, though they may get primarily infected also. Abscess & discharging sinus formation may at times follow infection or trauma. Spontaneous haemorrhage or iatrogenic haemorrhage may follow after attempt for aspiration or cytology. Respiratory difficulty and dysphagia may be associated with cystic hygroma of neck an oral cavity region.^[6]

As far as clinical findings are concerned, at time of presentation, it is compressible non-tender cystic in character on palpation, which exhibits intense trans-illumination. The radiological investigative procedure i.e. ultrasound, CT & MRI are adjunct to the armourey. For a localised lesion, an ultrasound is good enough to evaluate the extension. Ultrasound of the lesion usually features multicystic lesion with internal septations and no blood flow is detected on colour doppler^[6]. Extensive lesion needs CT & MRI especially when the lesion goes down to neck, mediastinum, or infiltrates larynx or tongue^[10]. It is helpful in ascertaining the extent of lesion and its relationship with important nerves & vessels. It helps in proper surgical planning and to reduce morbidity by keeping an option for sclerotherapy in left over disease. CT demonstrates multicystic, homogeneous, non-invasive density with low attenuation^[6].

The prenatal diagnosis of cystic hygroma using ultrasound is well documented in literature. These malformations are commonly localised in the nuchal region. An additional 20% are localised in axilla and rest 5 % are found in mediastinum, retroperitonium, abdominal viscera, groin and scrotum. Fetus with cystic hygroma can be associated with other anomalies in about 62% of cases^[6]. When diagnosed prenatally, it may be associated with turners' syndrome, various cardiac anomalies & trisomy syndromes and foetal hydrops^[6,7,8].

In this series of nine patients, all except one adult patient, presented with complaint of difficulty in feeding. All patients were prepared for surgical resection after proper evaluation by MRI. We preferred this investigation as all the patients had extensive lesions involving the whole of the submandibular space, lateral and anterior neck, floor oral cavity in 2 patients and even interscapular region crossing posterior triangle. MRI plays an important role in commenting on the floor oral cavity musculature involvement, involvement of tongue, status of thyrohyoid membrane, great vessels & nerves mostly importantly, hypoglossal and spinal accessory.

In our series, all the patients were treated with surgery. Usual indications for intervention are failure to thrive, respiratory distress, feeding difficulty, recurrent infections, spontaneous haemorrhage and cosmetic^[6]. Orvidas et al^[11] commented surgery as the primary treatment. Many other authors have suggested that the surgical excision is the choice of treatment for adult cystic hygroma as it is well circumscribed and the success rate is better^[12,13]. But in our series we could do total excision in all the cases successfully. Success of the surgery correlates with histopathology, encapsulation, complete excision, anatomical location and stage of the lesion^[14,15]. Even very low level of recurrence is commented following subtotal excision where very small amount tissue is left^[16]. Complex lesion may recur up to 10-20 % after complete resection and partial resection may recur in upto 50-100%^[17]. In our series, there is no recurrence till date.

Aspiration of cystic hygroma can be performed as a temporary measure to reduce the size of it and thereby reducing its pressure effects on respiratory and feeding passages^[6]. These cysts may produce milky, serous, sero-sanguinous or straw-coloured fluid, when aspirated with a wide-bore needle^[6]. The respiratory distress may be of severe nature necessitating a tracheostomy due to significant laryngeal or tracheal compressions by external and rarely laryngeal lymphangiomas^[6].

Surgical exploration of the complex cystic hygromas, involving deep and vital structures, is not an easy task. Extreme care has to be followed to avoid operative complications. The possible complications during surgery are damage to facial nerve & artery, spinal accessory nerve, carotid vessels, internal jugular vessels, thoracic duct, pleura and incomplete excision in case of infiltration to surrounding structures^[6]. The post operative complications observed after surgical excision of cystic hygroma are infection, haemorrhage, hypertrophic scar and lymph discharge through the wound^[6].

In all the cases, we have observed there is involvement of the posterior triangle. Surgical exploration showed the intimacy of the spinal accessory nerve in all the patients. The lesion always wraps around spinal accessory nerve. We realised in big lesions like those in our series, the accessory nerve is pushed up and is confronted just below the platysma and surgeon has to be extra cautious not to damage it. Sharp dissection seems to be the rule to give access to the all the areas. Area over the jugular needs extra care for resection with clarity, as the wall of the cyst lies very intimately with it, though a cleavage is always there to find.

There are other treatment modalities which were not tried in this series. Laser can be used for the treatment but with significant risk of skin damage^[18]. Sclerosant like boiling water, quinine, sodium morrhuate, urethane, iodine tincture, doxycycline and nitromin have been used in various studies but these agents are with low success rate and complications^[19, 20, 21, 22, 23]. Bleomycin is also used for sclerosis. Yura et al^[24] first used bleomycin as sclerosant. But it is associated with side effects like neutropenia, fever and pulmonary fibrosis. Another agent like interferon alpha is used in lymphangioma and haemangioma, which is associated with common side effects like neutropenia, fever and diarrhea^[25]. Another sclerosant agent OK-432 is in use and there is not much report of side effects. Okazaki et al^[26] recommended OK-432 injection therapy alone, for single cystic and macrocystic types and surgical excision after pre-treatment with OK-432 for microcystic and cavernous types. In our series, we adopted surgical excision as primary modality of treatment and leaving sclerotherapy for recurrence.

V. Conclusion

Cystic hygromas are rare benign neoplasm. Though easy to diagnose clinically, it needs good radiological evaluation. Complete surgical excision is possible even in very extensive lesions. Apart from other structure, accessory nerve demands an extra care as it is always entangled in the lesion and the first important structure to counter proceeding from the posterior triangle.

Compliance With Ethical Standards.

Conflict Of Interest – None.

Funding – None.

Informed Consent Obtained.

References

- [1] Ward FE, Hendrick JW, Chambers RG. Cystic Hygroma Of The Neck. *West J Surg Obstet Gynaecol.* 1950;58:41-7.
- [2] Ogita S, Tsuto T, Nakamura K, Deguchi E, Tokiwa K, Iwai N. O.K - 432 Therapies For Lymphangioma In Children: Why And How Does It Work? *J Paedtr Surg.* 1996;31:477-80.
- [3] Filston HC. Haemangioma, Cystic Hygromas And Teratomas In Of The Head And Neck. *Semin Pediatr Surg.* 1994;3:147-59.
- [4] Sichel JY, Udassin R, Gozal D, Koplewitz BZ, Dano I, Eliashar R. OK-432 Therapy For Cervical Lymphangioma. *Laryngoscope.* 2004;114:1805-9.
- [5] Galofre M, Judd ES, Perez PE, Harrison EJ Jr. Results Of Surgical Treatment Of Cystic Hygroma. *Surg Gynecol Obstet.* 1962;115:19-26.
- [6] Mirza B, Ijaz L, Sheikh A. Cystic Hygroma: An Overview. *J Cutan & Aesthet Surg.* 2010;3(3):139-44.
- [7] Chappius IIP - Current Aspect Of Cystic Lymphangioma In Neck. *Arch. Paediatric.* 1994;1(2):186-92.
- [8] Morley S E, Ramesar K C, Mcleod D A- Cystic Hygroma In An Adult: A Case Report. *J. R. Coll Surg. Edinburg* 1999;44(1):57-8.
- [9] Berry JA, Wolf JS, Gray WC. Squamous Cell Carcinoma Arising In A Lymphangioma Tongue. *Otolaryngology Head Neck Surg.* 2002;127:458-60.
- [10] Kennedy TL, Whitaker M, Pelitteri P, Wood WE. Cystic Hygroma/ Lymphangioma: A Rational Approach To Management. *Laryngoscope.* 2001;111:1929-37.
- [11] Orvidas L J, Kasperbauer J L. Paediatric Lymphangioma Of Head And Neck. *Annals Of Otolaryngology, Rhinology And Laryngology.* 2000;109(4):411-421.
- [12] Naidu SI, Mc Calla M R. Lymphatic Malformations Of The Head And Neck In Adults: A Case Report And Review Of Literature. *Ann Otol Rhinol Laryngol.* 2004;113:218-22.
- [13] Scheffer RP, Olsen KD, Gaffey TA. Cervical Lymphangioma In Adult. *Otolaryngol Head Neck Surg.* 1985;93:65-69.
- [14] Fliegelman LJ, Friedland D, Brandwein M, Rothschild M. Lymphatic Malformation: Predictive Factors For Recurrence. *Otolaryngol Head Neck Surg.* 2000;123:706-10.
- [15] De Serres L, Sie K, Richardson M. Lymphatic Malformation Of The Head And Neck. A Proposal For Staging. *Arch Otolaryngol Head And Neck Surg.* 1995;121:577-82.
- [16] Riechelmann H, Muehlfay G, Keck T, Mattfeldt T, Rettinger G. Total, Subtotal And Partial Surgical Removal Of Cervicofacial Lymphangiomas. *Arch Otolaryngol Head Neck Surg.* 1999;125:643-8.

- [17] Dillon P. Lymphatic And Venous Disorders. In Oldham KT, Colombam PM, Foglia RP. *Surgery Of Infants And Children: Scientific Principles & Practice*. Philadelphia. Lippincot-Raven; 1997, P1727-43.
- [18] Alani HM, Warren RM. Percutaneous Photocoagulation Of Deep Vascular Lesions Using A Fiberoptic Laser Wand. *Annals Of Plastic Surgery*. 1992;29(2):143-148.
- [19] Ibrahim AH, Kandeel A, Bazeed MF. Successful Non Surgical Management Of A Huge Life Threatening Cervicomediastinal Cystic Hygroma Case Report & Review Of Literature. *J Paed.Surg.Special*. 2009;3:48-50.
- [20] Mahajan J K, Bharathi V, Chowdhury SK, Samujh R, Menon P, Rao KL. Bleomycin As Intralesional Sclerosant For Cystic Hygromas. *J Indian Assoc Peditr Surg*. 2004;9:3-7.
- [21] Okada A, Kubota A, Fukuzawa M, Imura K, Kamata S. Injection Of Bleomycin As A Primary Therapy Of Cystic Lymphangioma. *J Paediatric Surg*. 1992;27:440-3.
- [22] Orford J, Barker A, Thonell S, King P, Murphy J. Bleomycin Therapy For Cystic Hygroma. *J Pediatr Surg*. 1995; 30:1282-7.
- [23] Zhong P Q, Xhi FX, Li R, Shu GY. Longterm Results Of Intratumorous Bleomycin A-5 Injection For Head And Neck Lymphangioma. *Oral Surg Oral Med Oral Pathol Oral Radiol Edodnone*. 1998;86:139-44.
- [24] Yura J, Hashimoto T, Tsuruga N. Bleomycin Treatment For Cystic Hygroma In Children. *Arch Jpn Chir*. 1977;46:607-14.
- [25] Reinhardt MA, Nelson SC, Sencer SF, Bostrom BC, Kurachek SC, Nesbit ME. Treatment Of Childhood Lymphangiomas With Interferon Alpha. *Journal Of Pediatric Haematology Oncology*. 1997;19(3):232-236.
- [26] Okazaki T, Iwatani S, Yanani T, Kobayashi H, Kato Y, Marusasa T, Et Al. Treatment Of Lymphangioma In Children: Our Experience In 128 Cases. *J Paediatr.Surg*. 2007;42:386-9.